



# Lift-(Gasless) Laparoscopic Surgery Under Regional Anesthesia

DANIEL KRUSCHINSKI, M.D.  
DIRECTOR ENDOGYN<sup>®</sup>

SHIRLI HOMBURG, PH.D.  
SCIENTIFIC RESEARCHER

INSTITUTE FOR ENDOSCOPIC GYNECOLOGY (ENDO GYN<sup>®</sup>)  
SELIGENSTADT, GERMANY

## ABSTRACT

**T**he objective of this Chapter was to investigate the feasibility and outcome of gasless laparoscopy under regional anesthesia. A prospective evaluation of Lift-(gasless) laparoscopic procedures under regional anesthesia (Canadian Task Force classification II-1) was done at three endoscopic gynecology centers (franchise system of EndGyn<sup>®</sup>). Sixty-three patients with gynecological diseases comprised the cohort. All patients underwent Lift-laparoscopic surgery under regional anesthesia: 10 patients for diagnostic purposes, 17 for surgery of ovarian tumors, 14 to remove fibroids, and 22 for hysterectomies. All patients were operated without conversion to general anesthesia and without perioperative or anesthesiologic complications. Lift-laparoscopy under regional anesthesia can be recommended to all patients who desire laparoscopic intervention without general anesthesia. For elderly patients, those with cardiopulmonary risks, during pregnancy, or with contraindications for general anesthesia, Lift-laparoscopy under regional anesthesia should be the procedure of choice.

**INTRODUCTION**

Thanks to novel developments, the indications for surgical endoscopy are being expanded continually. Almost all cases of surgical laparoscopy are performed under general anesthesia, because regional anesthesia is rarely tolerated as a result of the mechanical problems associated with the pneumoperitoneum, as well as the cardiopulmonary effects triggered. Few authors report on laparoscopic procedures under regional anesthesia; such reports are mainly confined to diagnostic procedures or tubal ligatures,<sup>1-3</sup> which, in rare cases, are also carried out for at-risk patients.<sup>4</sup>

Whereas general anesthesia and regional anesthesia produce similar long-term results,<sup>5</sup> the immediate postoperative course after general anesthesia often causes nausea and vomiting.<sup>6</sup> Opting for a form of anesthesia that provides for a postoperative phase free of side effects, such as vomiting, nausea, and/or circulatory problems, would seem to be preferable for laparoscopy—a minimally invasive procedure. Furthermore, the combination of pneumoperitoneum (hemodynamic side effects) and general anesthesia is often contraindicated for elderly women or patients with cardiopulmonary risks. In

addition, patients who fear general anesthesia, or undergo surgical procedures at short intervals, would be suitable candidates for regional anesthesia. Pregnant patients also would derive considerable benefits, as the effects of carbon dioxide (CO<sub>2</sub>) and mechanical problems associated with the pneumoperitoneum on the fetus are, as yet, unknown.

The concept of Lift-(gasless) laparoscopy is suitable for performing laparoscopic procedures under regional anesthesia. Lift-laparoscopy obviates the need for insufflation with CO<sub>2</sub>, thus precluding side effects such as metabolic acidosis or peritoneal hypoxia, as well as the poorly tolerated mechanical problems that emanate from the pneumoperitoneum, such as elevation of intraabdominal pressure or reduced perfusion of organs.<sup>7-12</sup>

The aim of this study was to investigate the perioperative management and outcome during and after Lift-laparoscopy under regional anesthesia.

**MATERIALS AND METHODS**

Either regional or general anesthesia was offered to patients who underwent Lift-laparoscopy. Following consultation with the surgeon and an explanatory

discussion with the Anesthesiologist, 15.3% (63/412) of patients opted for regional anesthesia as their anesthesia of choice. Prospective information was gathered on intraoperative pain, its localization, severity, and management. Postoperatively, occurrence of pain, nausea, and vomiting, as well as compliance, was evaluated in a discussion with the patient. Painkiller consumption was ascertained from entries in the patients' files. Pain intensity was evaluated three hours after surgery using a visual analog scale (subsidence of the effect of the peridural anesthesia). A patient questionnaire was used to record the duration, frequency, and intensity of nausea, vomiting, or both.

The indications for Lift-laparoscopy were diagnostic in 10 cases, ovarian tumor in 17, removal of fibroids in 14, and hysterectomy in 22. All patients with removal of fibroids and in cases of hysterectomy received a combined (spinal and epidural) regional anesthesia, because in such cases the procedure that included morcellation, could have taken longer than 90 minutes. All other patients underwent either spinal or epidural anesthesia. The operations were performed using Lift-laparoscopy with the AbdoLift (Storz, Tuttlingen) based on the technique described previously.<sup>13</sup> The head-down position was between 10° to 30° Trendelenburg.

**RESULTS**

All operations were performed successfully without converting to general anesthesia or other forms of anesthesia, and without operative or anesthesiologic complications. Three patients complained of mild shoulder pain during the operation, and was treated with piritramide. The head-down position was well-tolerated by all patients, and in no case were respiratory problems encountered. The mean duration of surgery was 47 (range: 35-65) minutes for adnexal surgery and 71 (range: 55-112) minutes for myoma enucleation. None of the patients complained of postoperative vomiting, nausea, or both. Pain intensity measured three hours after surgery was mild, and only four patients requested a painkiller. In general, mild postoperative shoulder or upper abdominal pain persisted for 12 to 24 hours, and none of the patients com-

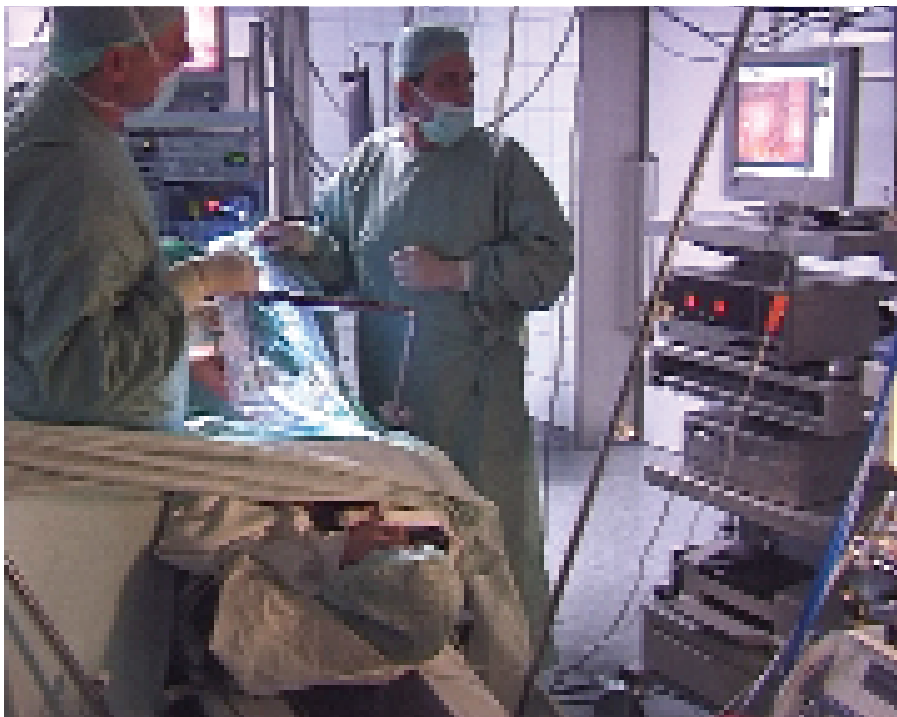

Figure 1. Intraoperative findings are demonstrated to the patient.



plained of shoulder pain for longer than 24 hours. Intraoperatively, the surgical site and treatment modalities were explained on an external monitor to patients who had expressed a desire for an intraoperative demonstration of the findings (Fig. 1).

Apart from one case, all patients were happy to have opted for surgery under regional anesthesia, stating that they would choose this surgical and anesthesia modality in the event of having to undergo surgery at a later date.

## DISCUSSION

This study is the first of its kind on a large number of patients who undergo gynecologic laparoscopic procedures under regional anesthesia. As the surgical spectrum for laparoscopic procedures in our specialty is being expanded continually, elderly women and at-risk patients are often operated on for several hours (eg, hysterectomy, myoma enucleation, carcinoma operation, etc.) with insufflation of CO<sub>2</sub>, head-down position, and general anesthesia, because the surgical spectrum for laparoscopic procedures in our specialty is being expanded continually. To eliminate the side effects and dangers associated with CO<sub>2</sub> and pneumoperitoneum, less-invasive surgical and anesthetic techniques must be explored. Patients often express a desire for an alternative to general anesthesia, because of the increasing fear of general anesthesia or

of "never waking up again."

Avoidance of the hemodynamic and systemic effects associated with artificial insufflation of CO<sub>2</sub> by resorting to Lift-laparoscopy means the body is subjected to less physiologic strain. Recent randomized trials were able to substantiate the claim that Lift-laparoscopy is less-invasive than CO<sub>2</sub> laparoscopy.<sup>14</sup> In the present study, Lift-laparoscopy required a significantly shorter convalescence period compared with that for patients who had undergone gas-laparoscopic surgical procedures. Bojahr<sup>15</sup> also was able to demonstrate, with prospective randomized trials (adnexal surgery, laparoscopic-assisted vaginal hysterectomy (LAVH) that lung compliance during Lift-laparoscopic procedures was not significantly affected intraoperatively. Conversely, the insufflation of CO<sub>2</sub> resulted in a significant decline in lung compliance, which was further exacerbated by the head-down position. When conducting the same procedures for healthy patients in the ASA Groups I and II with CO<sub>2</sub> laparoscopy, the cardiac and hemodynamic effects were more pronounced. The significant changes manifested intraoperatively for CO<sub>2</sub> laparoscopy with respect to the increase in CO<sub>2</sub> (end-expiratory CO<sub>2</sub>) and in pressure of carbon dioxide in arterial blood (PaCO<sub>2</sub>), followed by a decline in arterial pH, were not observed during Lift-laparoscopy. Therefore, it must be assumed that the use of Lift-laparoscopy confers cardiopulmonary and hemodynamic advantages in at-risk patients. The intensity of postoperative pain was

less pronounced in patients in the Lift-laparoscopy groups in both studies from the first postoperative day compared with after CO<sub>2</sub> laparoscopy.<sup>14,15</sup>

As demonstrated by our study, regional anesthesia also produces an important synergistic effect in terms of postoperative pain: in the immediate postoperative phase, markedly less pain is experienced due to the persisting regional anesthesia, thus obviating the need for other painkillers. Also, this immediate postoperative phase was viewed as positive by the patients due to the absence of the typical symptoms and side effects of a general anesthetic (nausea, vomiting, or both).

With appropriate patient management, no intraoperative problems, much less conversion to general anesthesia, are to be expected (in our patient group, none of the patients had to undergo secondary intubation). Of paramount importance is the fostering of positive communication between patient and surgical team before, during, and after surgery. The ability to work as a team, that comprises a surgeon, anesthesiologist, and surgical staff, is vital for successful conclusion of laparoscopy under regional anesthesia. In general, the level of noise must be reduced considerably, and any necessary conversations should be confined to the organizational content of the current operation to avoid engendering further anxiety in the patient who already finds himself in a stressful situation. The patient's willingness to cooperate, to breathe calmly and regularly, thus




Figure 2. The patient listens to a CD or watches a DVD using special goggles.

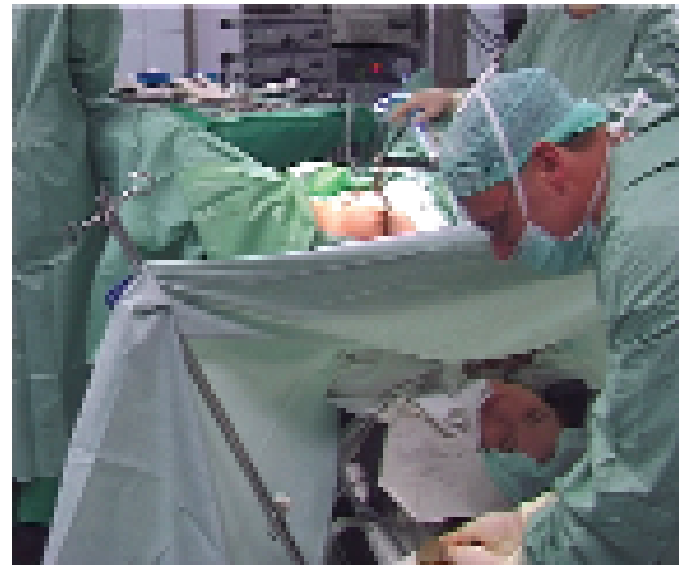

Figure 3. Intraoperative demonstration of the findings to the patient.

ensuring that the intestines that have been maneuvered from the pouch of Douglas remains in the upper and middle abdomen, is enhanced by speaking with her in a positive manner, with lots of praise. Just as in the case of a caesarean section, so the gynecological surgeon, when conducting laparoscopic surgery under regional anesthesia, should define a positive target for the waken patient—such as enucleation of a myoma or a cyst—as a signal that the operation will soon be over. It is beneficial in many cases if the patient can listen to a CD of her choice (Fig. 2), or watch a DVD using special goggles.

The head-down position was tolerated remarkably well. In no case were breathing problems or insufficiency of breathing depth manifest. Nor did patients find the Trendelenburg position onerous. Mild shoulder pain was observed in rare cases; in all probability, this was due to manipulation of the peritoneum and quickly resolved after administration of piritramide.

Spinal anesthesia is recommended for diagnostic or shorter operations, such as removal of cysts or subserous myomas. If it is not possible to estimate the duration of surgery accurately, combined regional anesthesia should be used. This also has proved its merit if the scope of the surgical procedure cannot be determined. Combined regional anesthesia offers a further advantage: should it prove necessary to expand the procedure intraoperatively, the duration of anesthesia can be prolonged at will using the peridural catheter that had been placed previously. Conversely, intubation would be necessary in the case of spinal anesthesia. For this reason, the author uses combined regional anesthesia preferentially for all operative Lift-laparoscopic procedures.

Lift-laparoscopic surgery under regional anesthesia is characterized by a high degree of patient satisfaction. Only the first patient in the study replied negatively to the question as to whether she would choose this form of anesthesia again. Her reason for this was so educational (she had felt "helpless and could not move any part of her body") that we modified our system of positioning immediately. Currently, when undergoing Lift-laparoscopic operations under

general anesthesia, both arms are positioned beside the patient, and they are able to move both arms freely during regional anesthesia. Being able to get an intraoperative demonstration of the findings was evaluated positively by patients (Figs. 1 & 3), as well as the fact that they could communicate with the surgeon or anesthesiologist; ie, had the ability to interact with the surgical team.

Lift-laparoscopy under regional anesthesia represents a real alternative to laparoscopic procedures under general anesthesia. The positive findings of this study should serve as an inspiration to conduct further studies to improve the outcome of laparoscopic surgery and make the "perioperative experience" as pleasant as possible for the patient. It would be advisable to conduct a randomized trial on pneumoperitoneum laparoscopy versus Lift-laparoscopy under regional anesthesia to definitively corroborate the findings. However, at-risk patients should be excluded from randomization due to the cardiopulmonary side effects of CO<sub>2</sub> insufflation. However, this group of patients would benefit most from laparoscopy under regional anesthesia.

The indication spectrum for Lift-laparoscopy under regional anesthesia is manifold. In addition to elderly patients, those with cardiopulmonary risks, or for whom laparoscopy or general anesthesia is contraindicated, can be operated on with the Lift-laparoscopic technique under regional anesthesia. The ability to use laparoscopic operations during pregnancy represents an important advance, because until now pregnancy was deemed to be a relative contraindication to laparoscopy and, hence, pregnant patients were excluded from this route of access and had to undergo laparotomy with its attendant hospital stay. Finally, as borne out by our experiences, this operative technique can be recommended for patients who have a fear of general anesthesia. **STI**

## REFERENCES

1. Aribag A. Epidural analgesia for laparoscopy. *J Obstet Gynaecol Br Commonw* 1973;80(6):567-8.

2. Caceres D, Kim K. Spinal anesthesia for laparoscopic tubal sterilisation *Am J Obstet Gynecol* 1978;13(2):219-20.

3. Endler GC, Magyar DM, Hayes MF, et al. Use of spinal anaesthesia in laparoscopy for in vitro fertilization. *Fertil Steril* 1985;43(5):809-10.

4. Pursnani KG, Bazza Y, Calleja M, et al. Laparoscopic cholecystectomy under epidural anesthesia in patients with chronic respiratory disease *Surg Endosc* 1998;12(8):1082-4.

5. Parker MJ, Unwin SC, Handoll HH, et al. General versus spinal/epidural anaesthesia for surgery for hip fractures in adults (Cochrane Review). *Cochrane Database Syst Rev* 2000;4:CD0000521.

6. Jaffe SM, Campbell P, Bellman M, et al. Postoperative nausea and vomiting in women following breast surgery: an audit. *Surg Endosc* 1998;12(8):1082-4 *Eur J Anaesthesiol* 2000;17(4):261-4.

7. Taura P, Lopez A, Lacy AM, et al. Prolonged pneumoperitoneum at 15 mmHg causes lactic acidosis. *Surg Endosc* 1998;12(3):198-201.

8. Wittgen CM, Andrus CH, Fitzgerald SD, et al. Analysis of hemodynamic and ventilatory effects of laparoscopic cholecystectomy. *Arch Surg* 1991;126:97-101.

9. McLaughlin JG, Bonnel BW, Scheeres DE, et al. The adverse hemodynamic effects related to laparoscopic cholecystectomy. *Anesthesiology* 1992;77(3A):70-7.

10. Ben-David B, Croitoru M, Gaitinin L. Acute renal failure following laparoscopic cholecystectomy: a case report. *J Clin Anesth* 1999;11(6):486-9.

11. Sharma KC, Kabinoff G, Ducheine Y, et al. Laparoscopic surgery and its potential for medical complications. *Heart Lung* 1997;26(1):52-64; quiz 65-7.

12. Koivusalo AM, Kellokumpu I, Ristkari S, et al. Splanchnic and renal deterioration during and after laparoscopic cholecystectomy: a comparison of the carbon dioxide pneumoperitoneum and the abdominal wall lift method. *Anaesth Analg* 1997;85(4):886-91.

13. Kruschinski D, Bojahr B, Kopjar M. Lift-laparoscopy with AbdoLift—A new concept of gasless laparoscopy. In: Levine R, Pasic R (eds), *Cookbook for gynecologic endoscopy*. London, New York, Parthenon Publishing, pp 303-318, 2001.

14. Larsen JF, Ejstrud P, Kristensen JU, et al. Randomized comparison of conventional and gasless laparoscopic cholecystectomy: operative technique, postoperative course, and recovery. *J Gastrointest Surg* 2001;5(3):330-5.

15. Bojahr B. Gaslose Laparoskopie—Evaluation einer Technik durch randomisiert prospektive Untersuchungen zu den Auswirkungen der mechanischen Retraktion der Bauchdecken im Vergleich zum CO<sub>2</sub>-Pneumoperitoneum bei gynäkologischen Operationen in Trendelenburgposition, Habilitationsschrift, Ernst-Moritz-Arndt-Universität Greifswald, 2001.