

# Gasless laparoscopy with conventional surgical instruments

Daniel Kruczynski, Uwe Schäffer and Paul G. Knapstein

Accepted for publication 3 May 1996

## Summary

**The main advantages of gasless laparoscopy arise from the use of conventional laparotomy instruments (clamps, scissors and needle pushers). The operative time, for example, for hysterectomy procedures decreases to about 60% of the time taken hysterectomy for using conventional gas techniques. During cauterization, smoke escapes immediately through the open trocars and may even be suctioned using a conventional suction tube. As far as the nursing team is concerned, the equipment is familiar as they use the same instruments and the same sutures as in laparotomy. High respiration pressure, caused by the elevated abdominal pressure, as well as hypercapnia, are avoided. Therefore this procedure may also be performed on higher risk patients. The advantages for the patients are the shorter operative time, pain reduction and fewer complications, while retaining all the benefits of minimally invasive surgery.**

*Keywords:* conventional surgical instruments, gasless laparoscopy, minimally invasive surgery.

## Introduction

Only after years of controversy has it been established that laparoscopic surgery may be the first-choice surgical procedure in several gynaecological disorders. Technological advances and surgical creativity have led to the increasing use of laparoscopic techniques by well-trained surgeons. Broader indications for laparoscopic surgery involved new operative techniques, and endo-GIA and coagulation replaced the time-consuming knot-tying procedures. There are now concerns that stapling and coagulation techniques may result in more complications. With the introduction of every new technique, there is a learning curve often associated with complications, but as the skill of the surgeon increases the complication rate falls and appears to be similar to that of the vaginal and lower

than of the abdominal approach.<sup>1</sup> There are, as yet, no studies in the literature based on controlled protocols that accurately determine the complication rates of the laparoscopic against the vaginal and abdominal approaches.

The main goal of our laparoscopic technique was to adapt the methods of open surgery to laparoscopic interventions, so that the preparation principles were identical to those in laparotomy. Clamps and ligatures were used to secure vascular ligaments. The main disadvantage of such an approach, using conventional CO<sub>2</sub> pneumoperitoneum, for laparoscopic procedures such as hysterectomy is the time necessary to apply the number of ligatures required. Laparoscopy is also time consuming because of the difficulties encountered in handling the instruments. The operative time often exceeds several hours which is difficult to justify for standard conditions particularly as this increased time may result in higher risk.

We did not want to compromise our operative techniques derived from open surgery, and we found that the gasless laparoscopic approach combines 'old' surgical principles and conventional instruments with the improvement of the 'new' videoendoscopy.

## Subjects and methods

From the middle of 1993 we have performed 131 gasless laparoscopic procedures (Table 1). The patients were placed in the lithotomy and 30-degree Trendelenburg position. We put into place a flexible intra-uterine probe, to allow mobilization of the uterus in all possible directions.

We used the gasless system from Origin Medsystems (Menlo Park, California, USA) which consists of two parts: the Laparolift (electrical distension arm) and the Laparofan (laparoscopic fan retractor). The powered elevator arm is attached to the operating table and can be lowered or raised with the push of a button (Fig. 1). The Laparofan has been designed in various shapes and lengths to allow elevation of all abdominal wall quadrants (Fig. 2). A connector provides attachment to the Laparolift. The Laparofan can rotate through 360 degrees to allow retraction in any direction and has a built-in spring gauge to determine the lifting force.

**D. Kruczynski MD**  
University of Bochum  
Bochum  
**U. Schäffer MD**  
**P.G. Knapstein MD PhD**  
University of Mainz  
Mainz  
Germany

*Correspondence:* D. Kruczynski, Department of Obstetrics and Gynaecology, University of Bochum, Knappschaftskrankenhaus, In der Schornau 23-25, D-44892 Bochum, Germany.

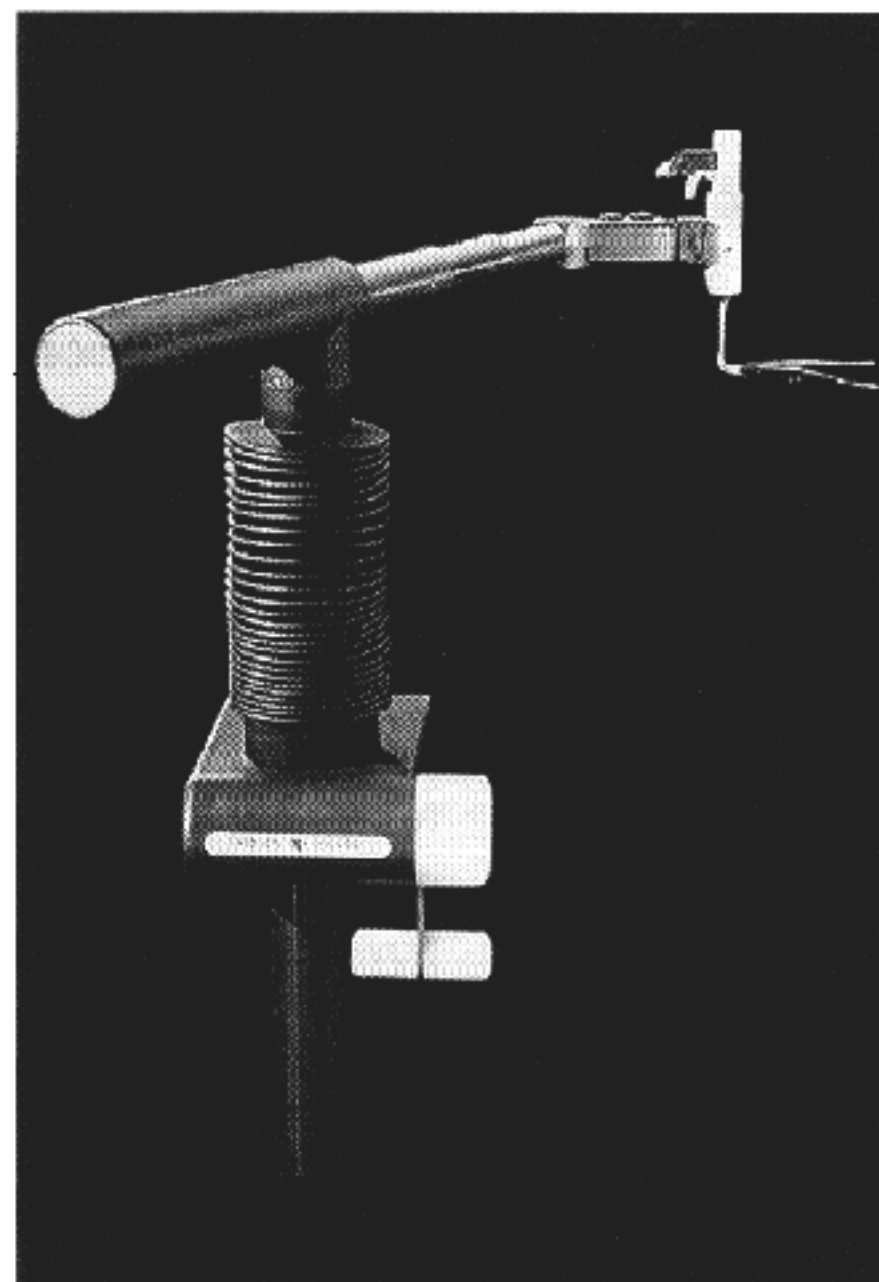
**Table 1** Number of gasless laparoscopic procedures performed between July 1993 and March 1995

Gasless procedure	<i>n</i>
Total hysterectomy	13
Supracervical hysterectomy	11
Myomectomy	31
Oophorectomy	23
Ovarian tumours	30
Others	23

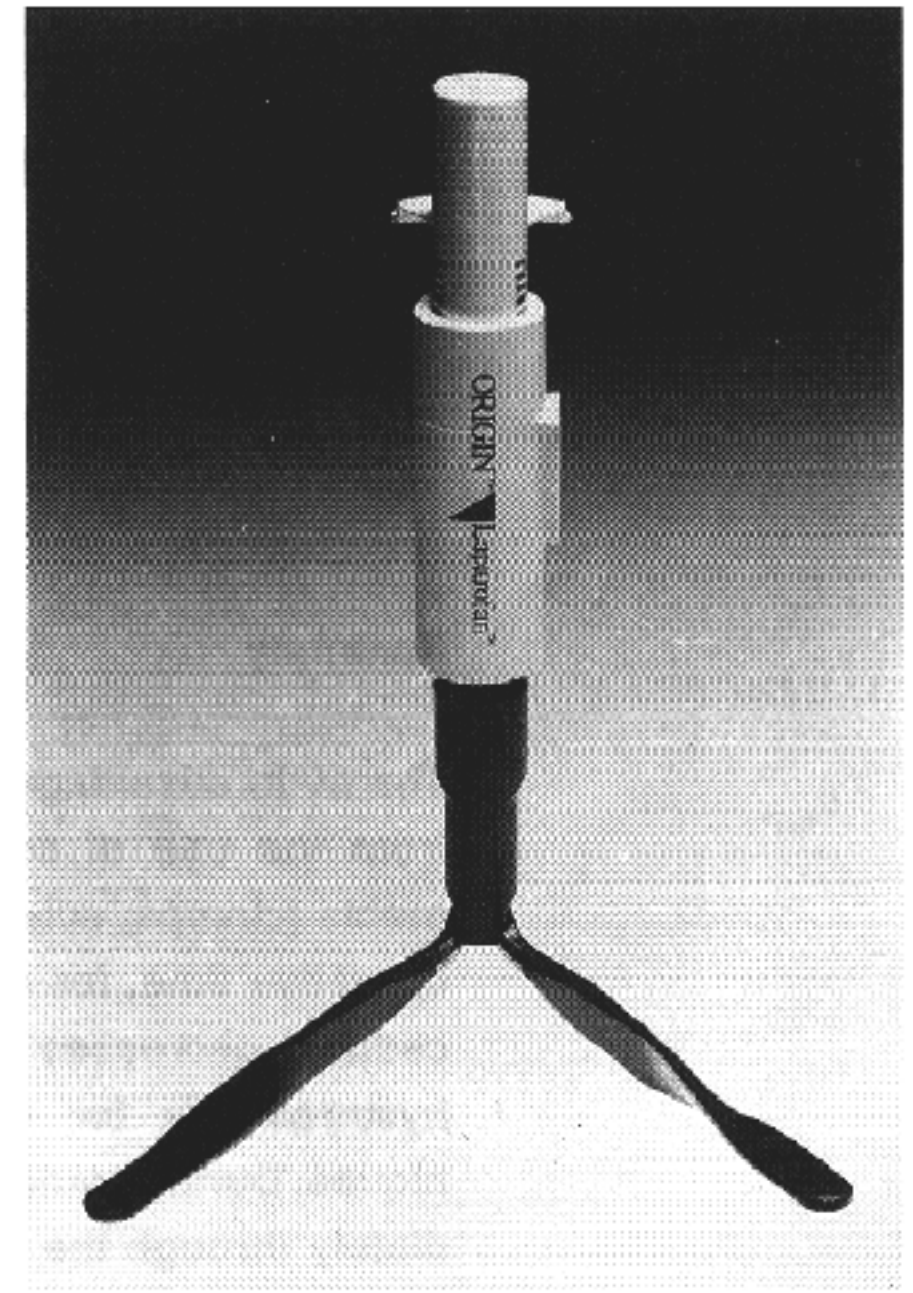
The Laparofan was introduced into the abdominal cavity via an umbilical minilaparotomy incision (Figs 3 and 4). For cosmetic reasons, we ensured, that this incision was no longer than 15 mm, and it was placed in the lower umbilical fold, so there was no difference from conventional laparoscopy. The position was checked with the endoscope inserted through the same incision, to confirm that no bowel or omentum was between the blades and the abdominal wall. After the blades were opened the elevator was connected to the Laparolift (Fig. 5) and the abdominal wall was elevated. Figure 6 shows the control view of the Laparofan shapes.

Trocar placement was identical to that used in gas laparoscopy; however, with gasless laparoscopy the two lateral trocars were 12 mm in diameter rather than 5 mm as in the 'gas' technique (Fig. 7). The 12-mm ports for gasless laparoscopy consist of flexible rubber material (Fig. 8).

Figure 9 shows the positioning of the operating team and of the instruments in the operating theatre. The surgeon stands on the left side of the table, at



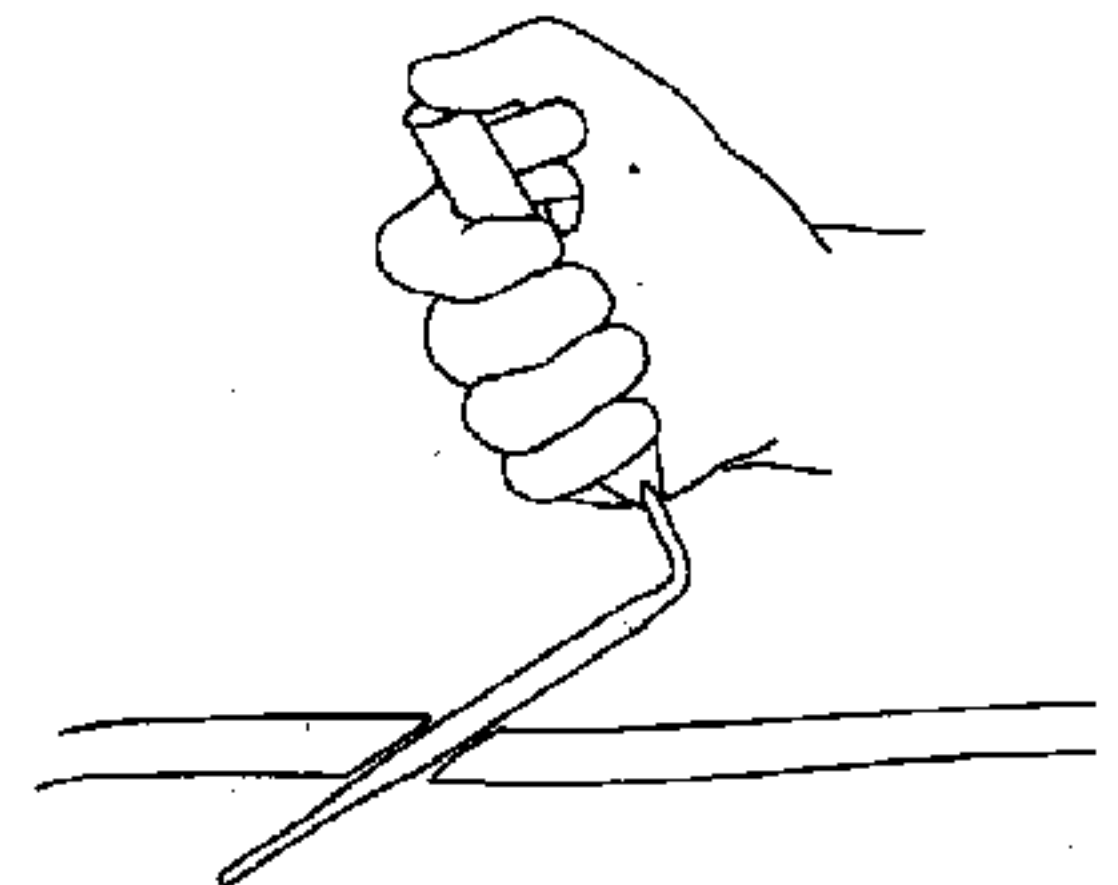
**Figure 1** Laparofan/Laparolift system from Origin Med-systems (Menlo Park, California, USA.) See text for description.



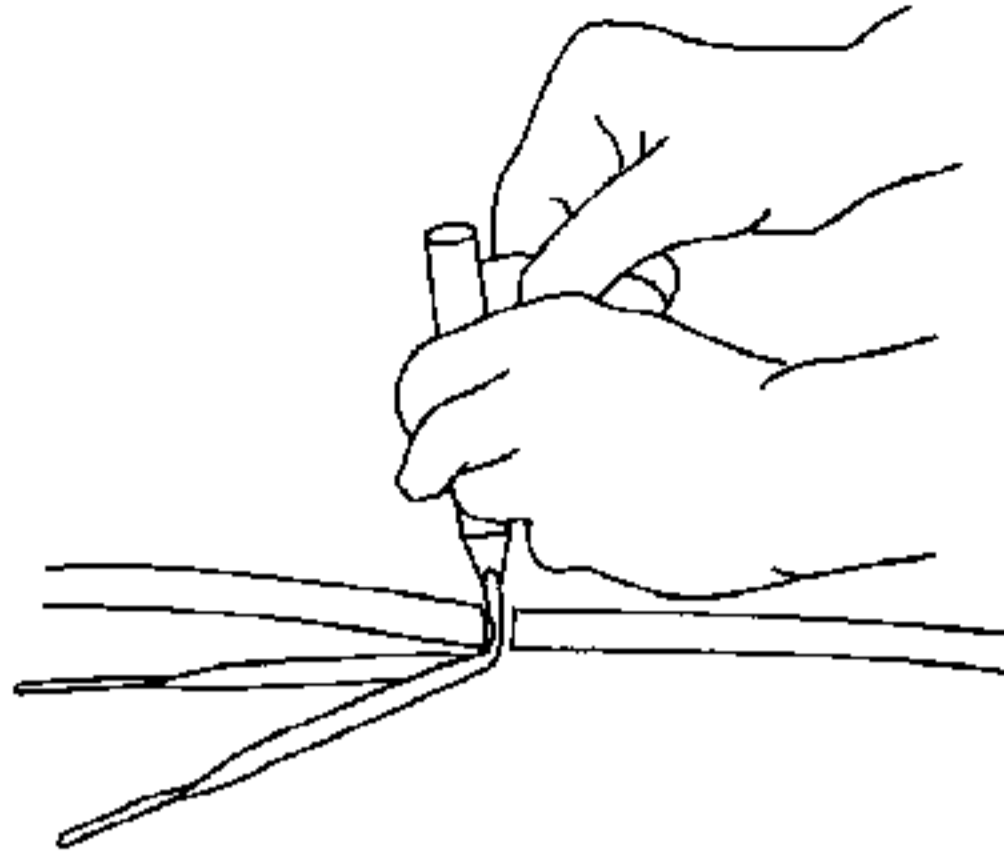
**Figure 2** One of the laparoscopic fan retractors (Laparofan). These are made in various shapes and lengths.

the level of the patient's thorax, the instrument table at his left side with the assisting nurse behind it. Both of them have free access to the instrument tables. The assistant surgeon is placed on the patient's right side, he usually holds the camera. If a second assistant is needed, he can be placed at the patient's head, which ensures that both surgeon and assistant are able to work bimanually. The video unit, including all the required equipment, is sited at the patient's foot. The Laparolift is connected to the operating table near the patient's shoulder.

Figures 10 and 11 show the use of conventional surgical instruments in dividing the right adnexa with conventional Wertheim clamps. The scissors (in this case endoscopic type) can be introduced through the same port as one of the clamps. After



**Figure 3** The Laparofan is introduced into the abdominal cavity via an umbilical minilaparotomy incision of length 15 mm.



**Figure 4** After introduction into the abdominal cavity the blades of the Laparofan are opened. The localization of the Laparofan must be controlled, using the optical system to confirm that no omentum or bowel is between the blades.

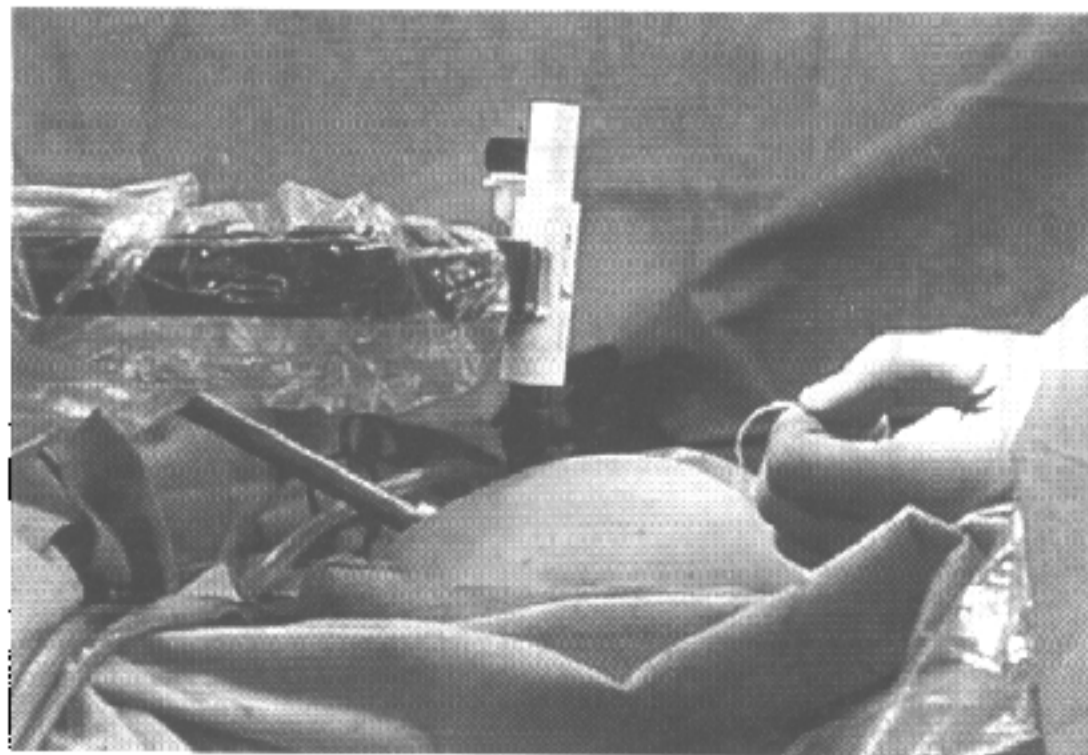
division of the tissue it can be stitched or ligated with extracorporeal ties. These steps can be performed individually, using clamps with stitches and ligatures or ligatures only.

### Results

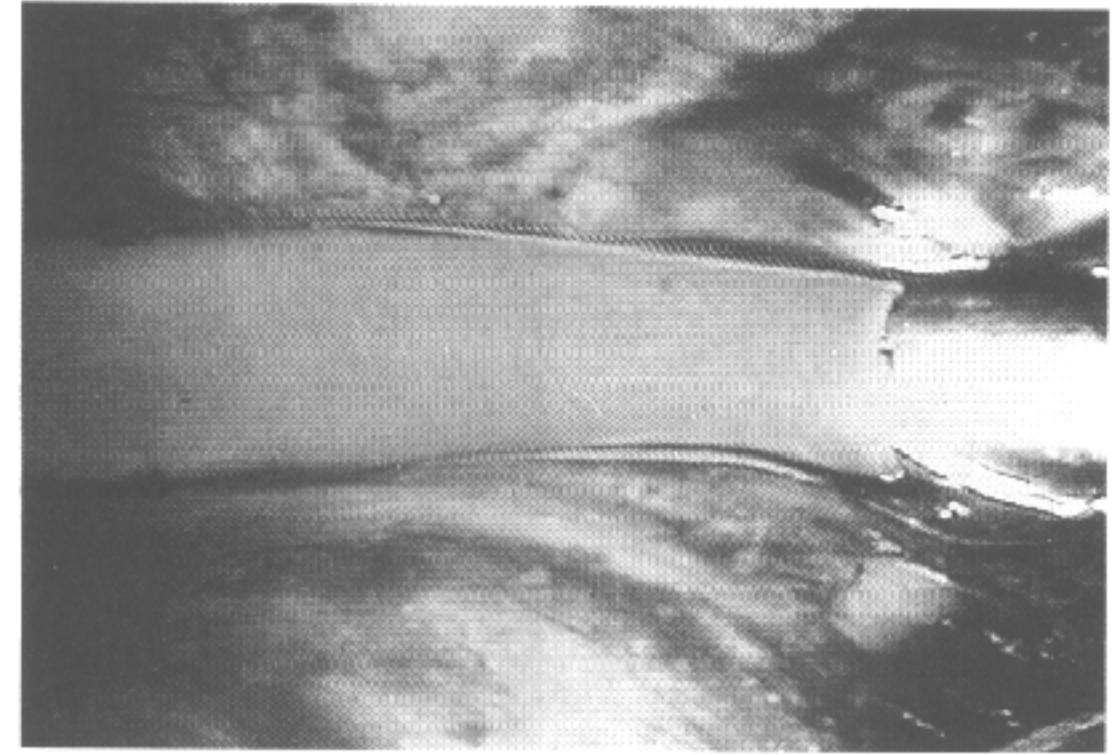
Gasless laparoscopy has many important advantages for the surgeon and staff: the operative time for hysterectomy and the nurses' table preparation time decreased by 45% (Table 2). Loss of time, where there is no action, is four times less with gasless than conventional gas laparoscopy; this was confirmed by our video clips (Table 2). Applying a ligature or setting a stitch is three times quicker using the gasless procedure (Table 2).

The main additional advantage is the possibility of using classical preparation techniques, with sponges, gauze strips and fingers, as well as conventional instruments such as the Wertheim clamp and preparation scissors.

Vision is not obscured by 'clouding up' of the



**Figure 5** After the blades of the Laparofan are opened, the elevator is connected to the Laparolift and the abdominal wall can be elevated. The optical system can be introduced with a glass trocar through the same incision.



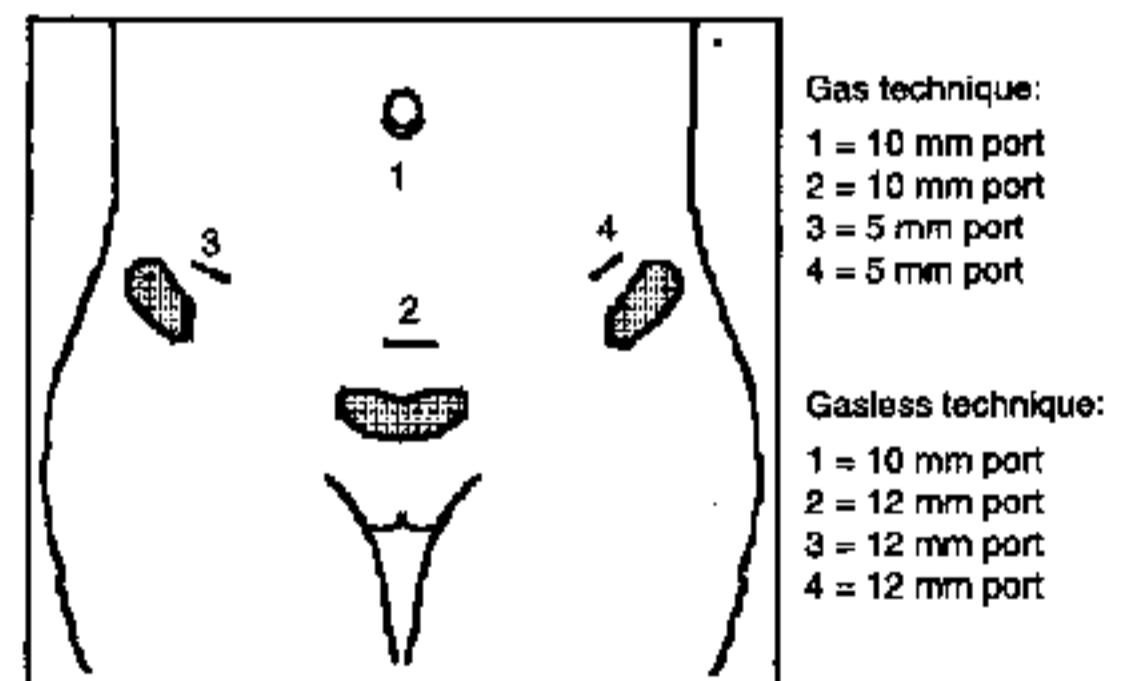
**Figure 6** The control view after elevation of the abdominal wall shows one of the Laparofan blades in the abdominal cavity.

scope. The nuisance of time-consuming and sometimes dangerous escape of gas is prevented. During cauterization, smoke escapes immediately through the open trocars and may even be suctioned using a conventional suction tube. The surgeon's fear of the patient's bleeding diminishes, as at any time bleeding can be visualized and controlled by conventional clamps and ligatures.

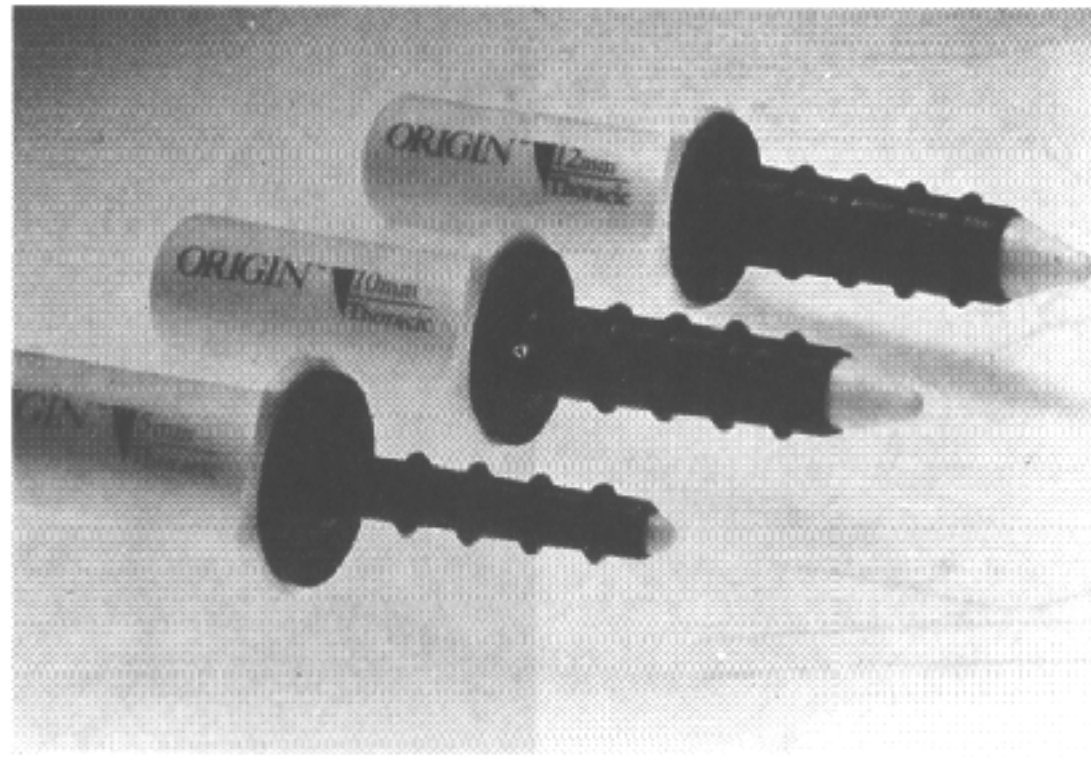
For the operating-room team the preparation for a gasless laparoscopy technique is simpler and easier. The table is prepared as for a conventional abdominal operation with standard suturing materials. The Laparofan and the rubber ports are added. The addition of some laparoscopic instruments (i.e. endo-scissors) makes the ideal combination as these instruments can often be chosen for use, and more than one may be placed through the same trocars as the clamps.

### Discussion

The use of carbon dioxide pneumoperitoneum for laparoscopic surgery leads to significant metabolic and haemodynamic changes.<sup>2,3</sup> Other effects of pneumoperitoneum, such as decreased cardiac output, elevated central venous pressure, increased



**Figure 7** Trocar placement is identical to that in gas laparoscopy, but with gasless laparoscopy the two lateral trocars are 12 mm in diameter, rather than 5 mm as in the gas technique.



**Figure 8** The 12-mm ports for gasless laparoscopy consist of flexible rubber material that allows insertion of conventional surgical instruments.

systemic vascular resistance and acidosis or the modulation of the peritoneum are currently being investigated. Another factor is the cost of gas laparoscopy, with the need for special, often disposable instruments. These instruments are expensive and completely different in design from those with which most surgeons are familiar. In addition, tissue and fluid in the instrument channels, may make them difficult, if not impossible, to sterilize.

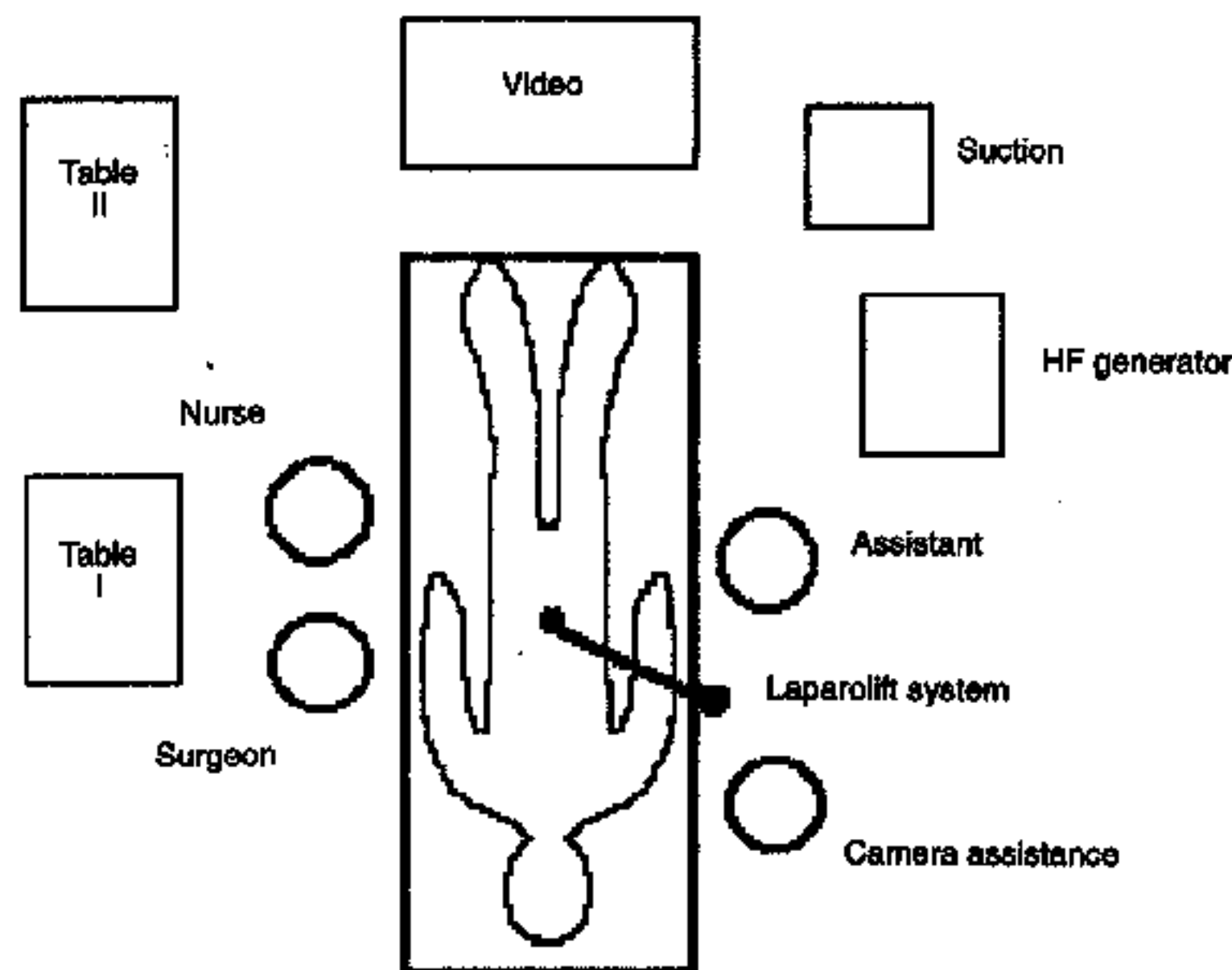
All these technical difficulties led to the need for the development of systems for gasless laparoscopy.<sup>4-7</sup> We use a planar lift retractor that allows excellent elevation of the abdominal wall and good exposure of the abdominal cavity. All the conventional instruments from 'open' gynaecological procedures can be introduced into the abdomen and used for most surgical interventions. These instruments have been perfected through many years of development and are reusable. Some gynaecological laparoscopic procedures are very controversial because of specific problems associated with gas laparoscopy; for example the use of a conventional

needle-pusher in suturing deep myometrial layers after myomectomy, the effectiveness of the microsurgical instruments that can be used for infertility surgery or division of tissue with the help of Wertheim clamps during hysterectomy. Using classical surgical principles and conventional instruments leads to a shorter duration for many laparoscopic procedures while using the same technique as in open abdominal surgery. In vaginal assisted hysterectomy procedures the two-way approach can be speeded up, avoiding the problems associated with gas loss.

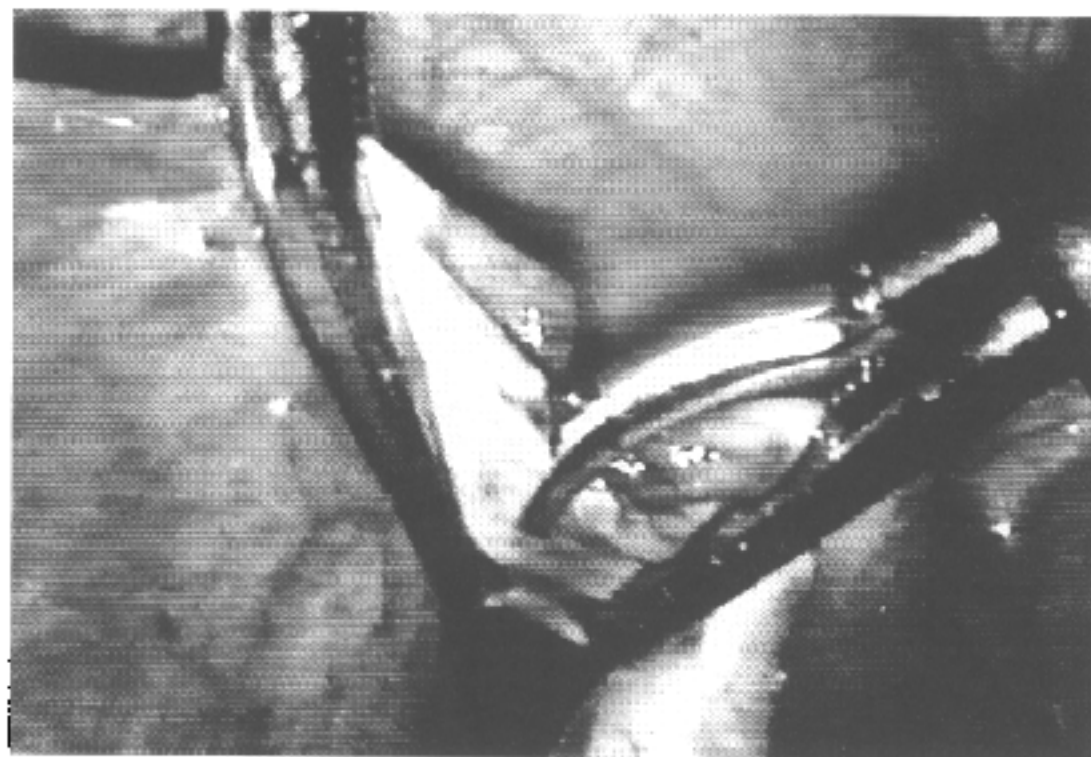
A reduction of postoperative nausea due to nitrous oxide absorption causing bowel distension, and the decrease of pain and consumption of analgesics are other advantages. Also the avoidance of complications, such as generalized emphysema, which occurred three times in our patients undergoing gas laparoscopy, or the hypothermia and diaphragmatic irritation, caused by the cold CO<sub>2</sub> and long operation times, leads to greater patient comfort.

A high percentage of intra-operative complications, such as vessel perforation with haemorrhage or gas intravasation, bowel perforations or damage to bladder or pelvic kidney, are associated with the creation of pneumoperitoneum using the Veress needle. In gasless laparoscopy such complications can be completely avoided using the 'open' laparoscopy technique.

The gasless procedure seems particularly useful in patients at high medical risk. High respiration pressures are avoided and so elevated abdominal pressure and hypercapnia are prevented. It is possible to operate using regional anaesthesia such as spinal or epidural block. The two larger lateral incisions necessary in gynaecological interventions



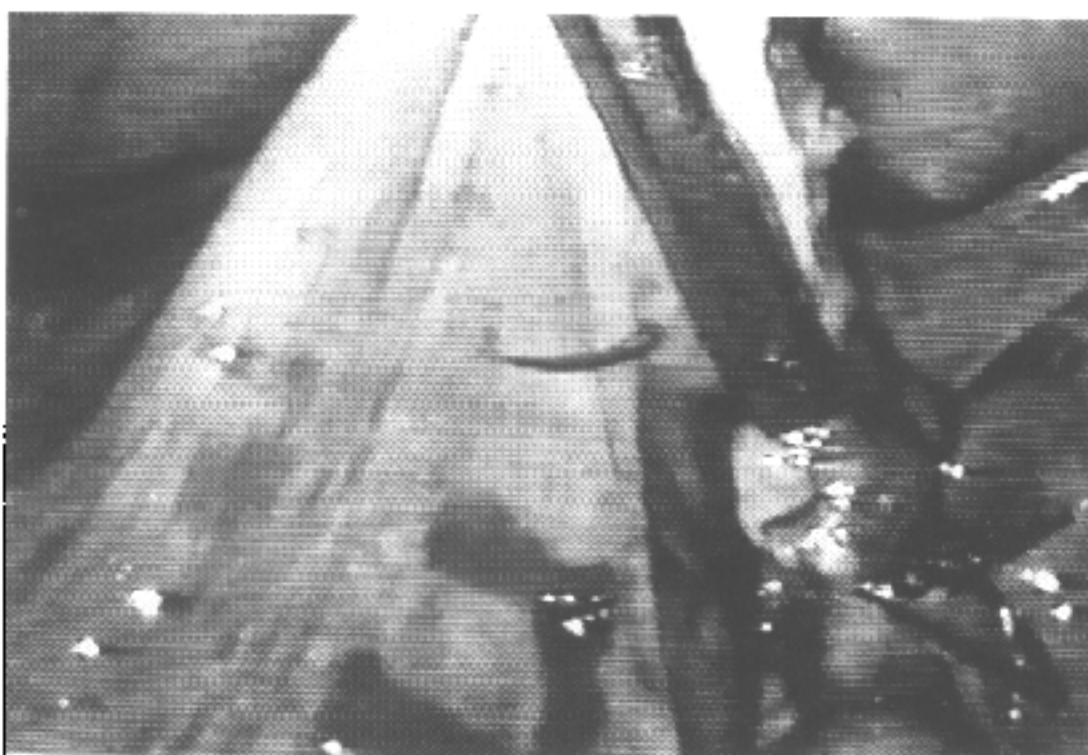**Figure 9** Position of the operating team, and of the Laparolift system which is connected to the operating table on the right-hand side.



**Figure 10** Dividing the tissue with endo-scissors, which can be introduced into the abdominal cavity through the same port as the right Wertheim clamp. One of the advantages of gasless laparoscopy is the possibility of combining the use of endoscopic and conventional instruments.

are not of cosmetic relevance, and do not lead to hernia of the abdominal wall if they are correctly closed. Pain in the area of the Laparofan placement was observed in none of the patients.

Metal shields would be preferable to plastic ones and a correction of the screw design is required. In obese patients the insertion of the Laparofan is very difficult and sometimes requires the use of broader incisions. In such patients the Laparofan branches cannot adequately elevate the abdominal wall. The issue of the single-use disposable Laparofan as well as the high cost (\$15 000)



**Figure 11** After separation the tissue can be stitched or ligated. These steps can be performed individually using clamps with stitches and ligatures or ligatures only; this can be varied according to the anatomical site. The possibility of performing the ligature with the help of extracorporeal ties without losing gas makes knotting procedures fast and simple.

**Table 2** Comparison of times (min) for surgical procedures in hysterectomies using gas-laparoscopic, gasless-laparoscopic, vaginal and abdominal approaches (from video analysis)

Average duration, min	Gas	Gasless	Vaginal	Abdominal
Table preparation	35	20	10	10
Operating time	180	100	75	115
Effective time	100	80		
Time without action	80	20		
Application of ligature	9	3		
Application of stitch	11	4		

of the complete equipment are problems that should receive further consideration by the manufacturing company.

In our opinion gasless laparoscopy will become established as a useful technique for hysterectomy, myomectomy and microsurgical procedures, as well as for surgical interventions of longer duration, and with the need for precise preparation, such as radical hysterectomy, or pelvic or para-aortic lymphadenectomy.

The concept of gasless laparoscopy with conventional instruments has given an extended scope to minilaparotomy. The combination of two methods, advanced videolaparoscopy and conventional surgery, but with the elimination of disadvantages of both, will ensure the advance of the laparoscopic laparotomy or 'laparoscotomy'.

## References

- 1 Jones RA. Complications of laparoscopic hysterectomy: 250 cases. *Gynaecological Endoscopy* 1995; **4**: 95-9.
- 2 Wolfe BM, Gardiner BN, Leary BF, Frey CF. Endoscopic cholecystectomy: an analysis of complications. *Archives of Surgery* 1991; **126**: 1192.
- 3 Wittgen CM, Andrus CH, Fitzgerald SD, Baudenstet LJ, Dahms R, Kaminski DL. Analysis of hemodynamic and ventilatory effects of laparoscopic cholecystectomy. *Archives of Surgery* 1991; **126**: 97.
- 4 Banting S, Shiml G, Vander Velpen G, Cushierl A. Abdominal wall lift: low pressure pneumoperitoneum laparoscopic surgery. *Surgical Endoscopy* 1993; **7**: 57.
- 5 Gazayerli MM. The Gazayerli endoscopic retractor model. *Surgical Endoscopy* 1991; **1**: 98-100.
- 6 Kitano S, Tomikawa M, Iso Y, Iwatao S, Gondo K, Moriyama M, Sugimachi K. A safe and simple method to maintain a clear field of vision during laparoscopic cholecystectomy. *Surgical Endoscopy* 1992; **6**: 197-8.
- 7 Maher PJ. The place of gasless laparoscopy? *Gynaecological Endoscopy* 1995; **4**: 155-8.